

Lingualnews.com

Volume 2, Number 1  
May 2004

### Original article

#### Lingual Orthodontics using the Light Wire bracket, Part 1

Dr E Mizrahi. BDS, DORTH RCS, FDS RCS, MSc, PhD, England

### Updates on Lingual and Adult Orthodontics

**Review:** Changes in the African American female profile as depicted in fashion magazines during the 20th century

Rafi Romano D.M.D., M.Sc Israel

### Review: Clinical Uses of Lasers in Orthodontics

Rashkovsky S. D.M.D, Israel

### New Ideas

**Review:** A Simplified lingual appliance.....

Wasserstein A . D.M.D., Israel

### Products & Materials

#### Lingual Self Ligating brackets

Moshe Davidovich D.D.S M.M.Sc Israel

### Clinical problems and solutions

#### Lingual Orthodontics in combination with FRC

Silvia Geron D.M.D., M.Sc Tel Aviv University, Israel

### Case presentations

#### Extraction case Treatment of an adult Class III malocclusion patient

Bruno Curriel D.D.S., PhD, Silvia Geron D.M.D., M.Sc, Tel Aviv University, Israel

### Aesthetic Dentistry

#### Bonding Bracket to a ceramic crown - understanding makes easy.

Daniel ziskind Dr. med. dent. Hebrew University, Israel

### Coming events

#### Courses and meetings in LO and aesthetic dentistry

### Smile

#### The smile of the month...

# Lingual News

Practical information on  
adult and lingual  
orthodontics



### Case presentations

#### Camouflage treatment of an adult Class III malocclusion patient with Lingual orthodontics

Bruno Curriel D.D.S., PhD,  
Silvia Geron D.M.D., M.Sc,  
Tel Aviv University, Israel



### Abstract

This case report shows the lingual Orthodontic treatment of a 27 years old male patient with Class III skeletal and dental relations, and severe lower crowding. The patient refused to undergo any orthognathic surgical procedure, and requested that an unseen orthodontic appliance be used.

The selected treatment option included extraction of both lower first bicuspid in order to unravel the crowding and to achieve a Class I canine relationship. This compromised option led to a camouflage of the facial appearance.

### Diagnosis

A 27 years old healthy male presented for treatment in the Department of Orthodontics at the Tel Aviv University School of Dental Medicine. His main complaint was that of crooked front teeth which, according to the patient, gives him an anesthetic appearance.

Clinical examination revealed that he had a dolicocephalic facial form with a long lower face height and facial asymmetry with the chin deviated to the right while the nose was deviated to the left. His profile was slightly concave prognathic, with normal nasiolabial angle and

competent lips (Fig 1).



Fig 1: pretreatment facial photographs

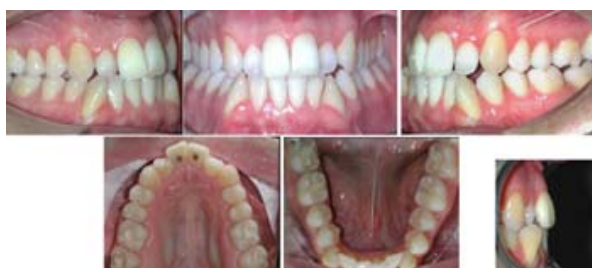

Fig 2: pretreatment intraoral photographs

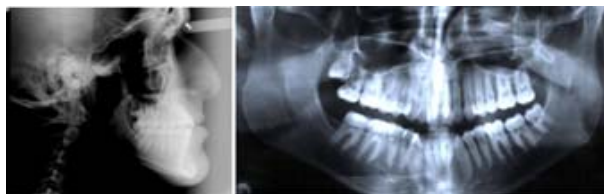

Fig. 3: Pretreatment panoramic and cephalometric radiographs

The intra-oral examination revealed an Angle's Class III malocclusion with 1 mm overjet and overbite. Both upper and lower midlines were shifted to the right relative to the face (1.5mm for the upper midline and 2.5mm for the lower one). An anterior crossbite was present in the area of both lower canines with their antagonist. Both arches were symmetric but not complimentary. The upper arch form was ovoid and more constricted than the lower arch form which was square (Fig 2).

Space analysis of the upper arch showed a lack of space of 3.5mm. In the lower arch, there was a lack of space of 12mm due to the lower blocked-out canines.

The peri apicals radiographs revealed previous endodontic treatments of the upper central incisors due to cariogenic causes. These teeth were found to be asymptomatic clinically and roentgenically. These teeth will require definitive restorations after the Orthodontic treatment has been completed.

Examination of the panoramic radiograph shows that tooth 28 is missing, 48 previously extracted, and 18 is unerupted/impacted. All other dental units are accounted for (Fig 3).

Cephalometric analysis revealed a hypodivergent mandibular plane angle with skeletal Class III relations. In addition, the maxillary incisors were found to be proclined while the mandibular incisors were retroclined (Fig 3).

#### Objectives of orthodontic treatment

- Achieve a Class I canine relationship
- Relieve the crowding in both arches.
- Achieve a functional occlusion with improved interincisal relationships. -Camouflage the Class III profile.

#### Orthodontic treatment plan

The primary treatment plan was a combination orthodontic-orthognathic surgical treatment option. Being that this was rejected by the patient, the secondary option of extracting two lower first premolars in order to achieve the above mentioned objectives. Due to the moderate crowding in the maxillary arch and to the Angle Classification affecting the profile of the patient, it was not necessary to extract also in the upper jaw. Therefore, it was decided to level and align the maxillary arch, while in the lower arch, it was

decided to level, extract the teeth 34 and 44, and finally close the spaces with moderate anchorage.

#### **Treatment alternatives**

In the present case, the alternative treatment option, consisting of the relief of crowding in the mandibular arch by first premolars extraction, would produce a compromised result concerning the prognathic profile of the patient.

The extraction of the second premolars in the lower arch was considered as well, since it is more difficult to close lower first premolars extraction spaces with the lingual technique (1). However since the crowding was concentrated in the anterior region it was decided to extract close to it and relieve the crowding early during the treatment.

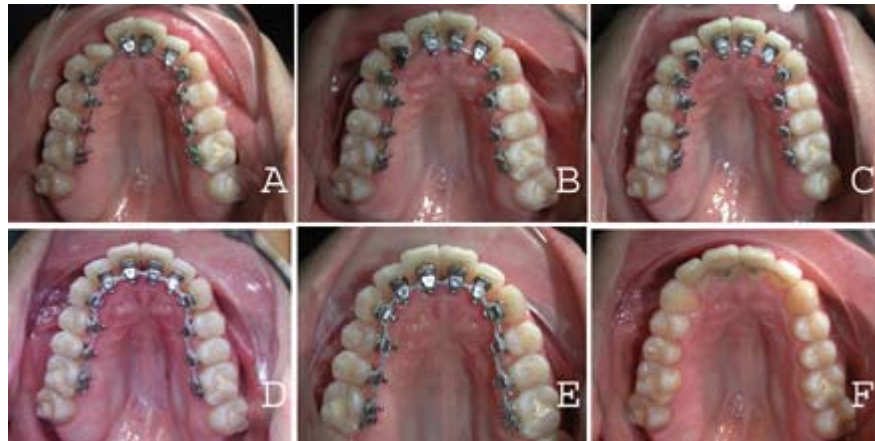
#### **Treatment progress**

Lingual crown height was sufficient for optimum bracket positioning and there were no restoration that would preclude or complicate lingual bonding.

The Ormco lingual fixed orthodontic appliance was used, with 0.018x0.025-inch slot brackets for canine to canine and 0.022x0.028-inch slot brackets for the posterior teeth (i.e. bidimensional technique). All brackets were prepared for indirect bonding in office, using the indirect Lingual Bracket Jig (LBJ) technique (SILAM)(2).

The transfer tray was prepared from silicone impression material. The indirect bonding material used was Custom IQ (Reliance Co), according to the manufacturer instructions.

Treatment was initiated by bonding the upper arch and inserting a 0.017x0.017 inch CuNiTi (Ormco) together with an opened NiTi coil spring between left cuspid and left central incisor in order to create sufficient space for bonding a bracket on tooth 22 (Fig 4A). By the next appointment, adequate space was created by proclination and expansion for the upper lateral incisor which was bonded directly with the LBJ and engaged on the archwire (Fig 4 B-C).

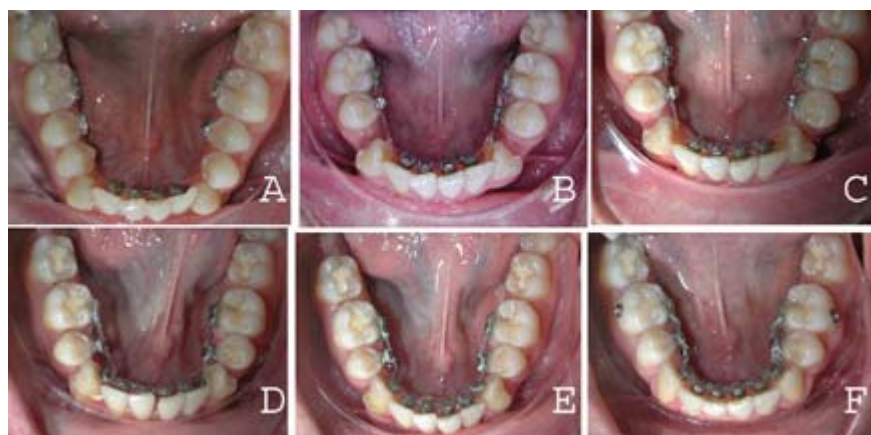

**Fig. 4: Alignment stage of upper arch**

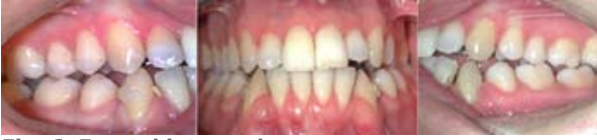After levelling and alignment of all teeth, a power chain was used on a 0.016x0.022 inch Stainless Steel wire to close residual spaces (Fig 4D-E). Finally, all teeth were co-ligated using steel ligatures, a TMA .0175x.0175 wire was used for finishing bends and lingual root torque on both lateral incisors .

Debonding of the upper arch was done after 12 months of treatment(Fig 4F), while the treatment of the lower arch continued.

In the lower arch all teeth were bonded except first premolars, because of the future extractions, second molars, which were not needed for anchorage, and the canines which could not be bonded due to their malalignment (Fig 5A).



**Fig. 5. alignment and leveling of lower arch**



**Fig. 6. Frontal intraoral view during lower canines rotation**

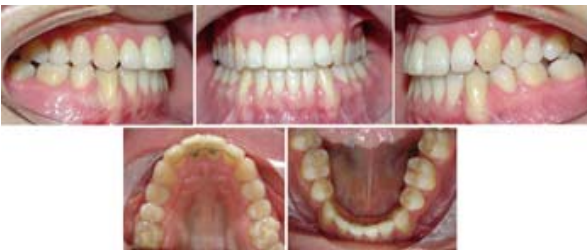The four lower incisors were leveled separately from the posterior teeth, using a section of 0.0175 inch Respond (Ormco) wire. On each side, the brackets of the second premolar and the molar were placed on the same horizontal level to enable the insertion of a rigid arch wire, 0.016x0.022 inch Stainless Steel, thus creation a consolidated anchorage unit for retraction of both cuspids. This was performed after the extraction of the first premolars, three weeks after the initial bonding. Clear plastic buttons (Unitec co) were bonded to the labial surfaces of the canines and an elastomeric chain stretched first between them to affect simultaneous derotation and secondly to the posterior teeth for the retraction. (Fig 5 B-C, Fig 6)).

Replacing the buccal buttons, lingual brackets could then be bonded on the derotated canine and 0.016 inch nitinol was inserted to continue leveling and alignment of the arch (Fig 5D-E). Finally, a 0.0175x0.0175 inch TMA archwire was inserted for correcting the lower incisors torque and finishing (Fig 5F).

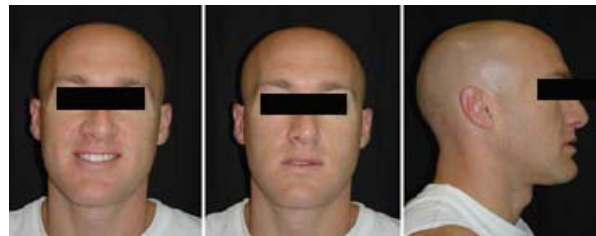In order to correct the midlines, the patient was instructed to wear intermaxillary elastics from the lower left canine to the upper clear vacuum-formed removable retainer. The overjet was corrected with Class II elastics.

### Retention

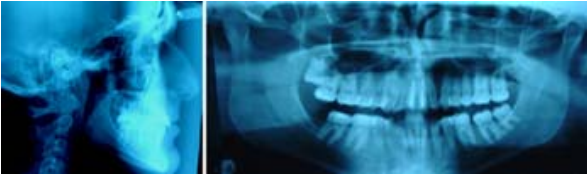The teeth were retained using a bonded 0.0195 twist flex wire from maxillary lateral to lateral incisors (the patient refusing to restore the central incisor at that time) and from mandibular canine to canine. In addition, clear vacuum-formed removable retainers were delivered for a night-time use.



**Fig. 8: post treatment intraoral photographs**



**Fig 7: posttreatment facial photographs**



**Fig. 9: Pretreatment panoramic and cephalometric radiographs**



**Fig 10: Superimposition of the pretreatment and the posttreatment cephalograms**

### **Treatment results**

Significant improvement in the patient smile and profile was noted, the Class III profile was improved, but still the protruding chin compromised the result concerning the prognathic profile of the patient (Fig 7).

Crowding in the upper and lower arch was relieved and proper functional occlusion was created with overjet and overbite within normal limits. Class I canine relations was achieved on the left side but was not on the right side. (Fig 8).

Periapical and panoramic radiographs show proper tooth positions and no detectable root resorption (Fig 9)

Superimposition of the pre- and post-treatment cephalograms showed slight retraction of the upper and significant retraction of the lower incisors. retraction of the lower lip followed the retraction on lower incisors, contributing to the camouflage of the Class III profile (Fig 10).

Treatment objectives were achieved in 22 months of treatment.

### **References**

1. Takemoto K. Anchorage control in lingual orthodontics. In: Romano R, editor. Lingual orthodontics. Hamilton, Canada: BC Decker; 1998. p.75-82.
2. Geron S The lingual bracket jig. J Clin Orthod. 1999;32:457-462.